

Case Report

Fatal Intracranial Haemorrhage due to HPA-2b Incompatible Foetal Alloimmune Thrombocytopenia and Antenatal Management of Subsequent Pregnancy

Arun Francis¹, Sarat Chandra G¹, Aruna Rajendran^{2*}

1. Department of Neonatology 2. Division of Paediatric Haematology Oncology, Sri Ramachandra University, Porur, Chennai, Tamil Nadu, India.

Abstract

Intracranial hemorrhage as a presenting feature of neonatal Alloimmune thrombocytopenia is an uncommon manifestation and is a predictor of recurrent risk in future pregnancy. The index child had an uncommon Human Platelet Antigen (HPA-2b) causing fetomaternal incompatibility leading to in-utero intracranial hemorrhage. The rarity of this antigen in the population posed a challenge in establishing the diagnosis. With the aid of HPA genotyping the father was found to be heterozygous for this antigen which led to proceed with the antenatal diagnosis of the condition in the subsequent pregnancy.

Key words: Neonatal Alloimmune Thrombocytopenia, NAIT, Human Platelet Antigen, Antenatal Diagnosis, Intracranial Hemorrhage

Introduction

Neonatal Alloimmune thrombocytopenia (NAIT) is the most common cause of severe thrombocytopenia in a term neonate. In most instances, this disorder causes mild bleeding but rarely it can lead to intracranial haemorrhage (ICH). Intracranial bleed has a higher recurrence rate and more severe manifestations in the subsequent pregnancies. We would like to share our experience in diagnosing NAIT in a new born child who had ICH as the presenting feature and the antenatal management in the subsequent pregnancy.

Case report

A 28 year old woman presented at 37 weeks of gestation with an incidentally detected fetal ICH and had a history of miscarriage in

the first pregnancy (Fig. 1). The earlier antenatal scan done at 32 weeks of gestation was apparently normal. The baby was delivered by a caesarean section (in view of a large secondary hydrocephalus) and was neurologically depressed requiring ventilation at birth. Investigations revealed neonatal thrombocytopenia and anaemia (Hb 86 g/L, TLC $17.6 \times 10^9/L$, DLC- P 62%, L 30%, M 5%, E 3%, platelets $15 \times 10^9/L$). The mother's platelet count was normal ($270 \times 10^9/L$) and ANA was negative. Initial screening for NAIT with HPA 1a and 5a of both the parents and the child was non-contributory. Since there was no other explanation for thrombocytopenia and intracranial bleed, extended human platelet antigen typing of the family was done which showed incompatibility of HPA 2b. The father was heterozygous (HPA 2a/2b), mother homozygous (HPA 2a/2a) for the HPA 2a locus and the baby resembled the father (HPA 2a/2b) (Table 1). The index child succumbed within 48 hours of birth. In the next subsequent pregnancy a year later, the HPA antigen typing of the fetus done from chorionic villous sample was HPA 2a/2a, resembling the mother at 14th week of gestation. Maternal contamination of the sample was ruled out using FVIII ST14 marker. As there was no HPA in-

*Corresponding Author

Dr. Aruna Rajendran,
Assistant Professor,
Division of Paediatric Haematology Oncology,
Department of Paediatrics,
Sri Ramachandra Medical College & Research
Institute, Porur, Chennai-600116.
E-mail: deararuna@yahoo.com
Received 22th Jun 2016, Accepted 20th June 2016

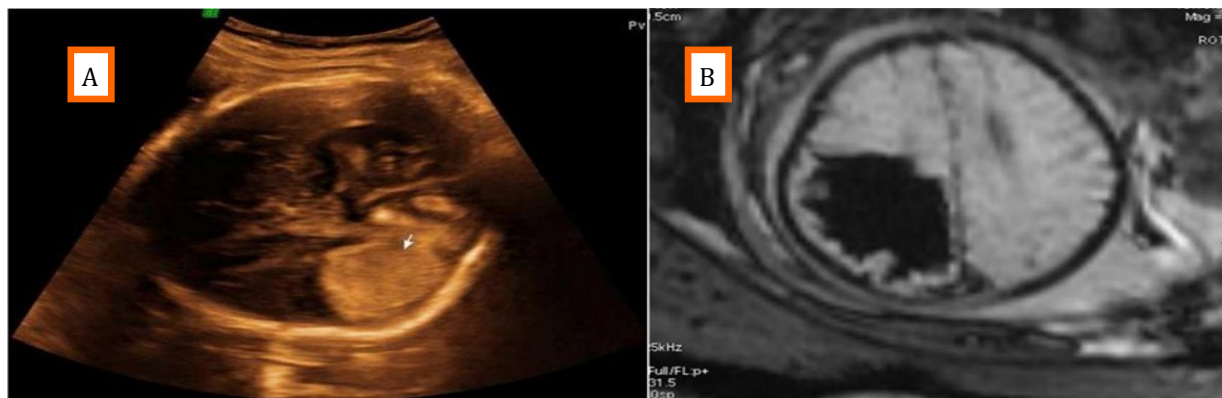


Fig 1. A. Foetal sonogram at 37 weeks of gestation. B. MRI showing intraparenchymal haemorrhage in the left paratrigonal, temporo-parieto-occipital regions with extension into the ventricles, basal cisterns and sulcal spaces.

Table 1. Extended Human Platelet Antigen typing of the parents and index child.

	Human Platelet Antigen Genotyping						
	HPA-1	HPA-5	HPA-2	HPA-3	HPA-4	HPA-6	HPA-15
Mother	HPA-1a/1a	HPA-5a/5a	HPA-2a/2a	HPA-3a/3b	HPA-4a/4a	HPA-6a/6a	HPA-15a/15a
Father	HPA-1a/1a	HPA-5a/5a	HPA-2a/2b	HPA-3a/3b	HPA-4a/4a	HPA-6a/6a	HPA-15a/15a
1 st baby	HPA-1a/1a	HPA-5a/5a	HPA-2a/2b	HPA-3a/3a	HPA-4a/4a	HPA-6a/6a	HPA-15a/15a

compatibility between the mother and child, no active intervention was provided. The mother delivered a healthy female baby at term and the platelet count was normal at birth (360 x 10⁹/L).

Discussion

NAIT is the platelet counterpart of hemolytic disease of the newborn (HDN). Unlike HDN, this condition affects in the first pregnancy.^[1] Fetal platelets carries certain complex glycoproteins (GP) on their surface which are classified as GP I to GP X. GP expresses the antigens HPA on their surface. At least 33 HPA antigens are typed till date.^[2] Twelve of above antigens exists as six bi-allelic antigens where the designation ‘a’ and ‘b’ implies the higher and lower frequency allele respectively. The incompatibility between platelet alloantigen of the fetus and the mother leads to production of maternal antibodies. These antibodies crosses placenta and destructs the fetal platelets leading to fetal and later neonatal thrombocytopenia. NAIT usually manifests as isolated skin

bleeds (47%) in the immediate new born period.^[3] Major bleeding into vital organs like brain, gut or lungs is uncommon but may lead to long term morbidities. Intracranial hemorrhage is seen 7 to 26% of NAIT and it occurs predominantly in the fetal life (82%) and commonly prior to 28 weeks of gestation.^[3] ICH can result in death or long term neurodevelopmental disability such as blindness, cerebral palsy, seizure disorder and autism.^[4] NAIT is suspected when baby has an isolated thrombocytopenia and relatively well looking. NAIT could well fit into diagnosis when the other causes of thrombocytopenia such as infections, disseminated intravascular coagulation, congenital anomalies, history of maternal thrombocytopenia and maternal drug intake are ruled out. Incompatibility between maternal and paternal HPA will confirm the diagnosis of NAIT. Among caucasian population, 95% of NAIT are due to HPA-1a and HPA -5b incompatibility and 5% is due to incompatibility to HPA 2, 3 and 15.^[5] Among asians, incompatibilities are common with HPA -4b and HPA-5b.^[2]

In such a scenario where clinical suspicion of NAIT is strong, repeat antibody testing at 6 weeks to rule out false negativity or extended parental and neonatal antigen typing is warranted because it holds a high relevance in managing the subsequent pregnancy. In our index case, extended HPA typing identified maternal incompatibility to HPA-2b. Regarding HPA 2b, only 5% of the Asian population has HPA 2a/2b and 95% have HPA 2a/2a. Incompatibility to HPA 2b is known but a rare cause of NAIT. Goldman et al, have reported a similar case with HPA 2b incompatibility presenting as fetal intracranial hemorrhage at 34 weeks of gestation.^[6] In the Indian context, NAIT is largely under diagnosed.

Management in subsequent pregnancies ICH in previous pregnancy is the strongest positive predictive factor to determine the risk of recurrence in future pregnancy and the disease severity.^[9] Father's zygosity will determine the recurrence risk in next pregnancy.^[10] In case of paternal heterozygosity for the given HPA as in our index case (HPA 2a/2b), fetal HPA genotyping can guide the antenatal management. Sample for fetal HPA genotyping can be obtained from invasive methods such as amniotic fluid or chorionic villous samples (CVS). In our case, the fetal HPA obtained from CVS was homozygous for HPA 2a/2a, resembling the mother. Maternal HPA alloantibody levels can be done to identify the incompatibility. However, the titre does not correlate well with the clinical severity and severe disease can occur even with low antibody titers.^[9] With the aid of these advanced antenatal investigations and father's heterozygous state, we could avoid the antenatal use of weekly 1g/ kg Intravenous immunoglobulin to the mother indicated from 20 weeks of gestation with is highly expensive.^[3]

Conclusion

NAIT should be suspected as a cause of severe thrombocytopenia in a term neonate. In cases where the common HPA incompatibilities are ruled out, search should be undertaken to look for the uncommon HPA incompatibilities. In view of the risk of recurrence in future pregnancy, it is essential to confirm the diagno-

sis of NAIT. Further, HPA genotyping of the parents will aid in identifying father's zygosity. If the father is heterozygous for the HPA, then in subsequent pregnancies the recurrence risk of NAIT can be determined based on fetal genotyping.

Abbreviations

NAIT-Neonatal Alloimmune Thrombocytopenia, HPA-Human Platelet Antigen, ICH-Intra Cranial Hemorrhage, ANA-Anti Nuclear Antibody, GP-Glyco Protein, CVS -Chorionic Villous Sampling

References

1. Kaplan C. Neonatal alloimmune thrombocytopenia. *Haematologica* 2008;93: 805-07.
2. Curtis BR, McFarland JG. Human platelet antigens 2013. *Vox Sang* 2014;106: 93-102.
3. Espinoza JP, Caradeux J, Norwitz ER, Illanes SE. Fetal and Neonatal Alloimmune Thrombocytopenia. *Rev Obstet Gynecol* 2013;6: e15-21.
4. Porcelijn L, Van den Akker ES, Oepkes D. Fetal thrombocytopenia. *Semin Fetal Neonatal Med* 2008;13: 223-30.
5. Bussel JB, and Primiani, A. Fetal and neonatal alloimmune thrombocytopenia: progress and ongoing debates. *Blood Rev* 2008;22: 33-52.
6. Chakravorty S, Roberts I. How I manage neonatal thrombocytopenia. *Br J Haematol* 2012;156: 155-62.
7. Goldman M, Trudel E, Richard L, Khalife S, Spurll GM. Neonatal alloimmune thrombocytopenia due to antiHPA2b. *Immuno hematol* 2003;19: 43-46.
8. Mohanty D, Kulkarni B, Ghosh K, Nair S, Khare A. Human Platelet Specific Antigens and their Importance. *Indian Pediatrics* 2004;41: 797-805.
9. Vinograd CA, Bussel JB. Antenatal treatment of fetal alloimmune thrombocytopenia: a current perspective. *Haematologica* 2010;95: 1807-811.
10. Murphy MF, Williamson LM. Antenatal screening for fetomaternal alloimmune thrombocytopenia: an evaluation using the criteria of the UK National Screening Committee. *Br J Haematol* 2000;111: 726-32.